

Endoscopic resection of a cardia gastrointestinal stromal tumour (GIST) after echoendoscopy

David Corrêa Alves de Lima, Luiz Ronaldo Alberti

Biogastro Clinic and Federal University of Minas Gerais, Brazil.

Acta Gastroenterol Latinoam 2012;42:230-233

Summary

Gastrointestinal stromal tumours (GISTs) previously were thought to represent smooth muscle tumours of the gastrointestinal tract and were formerly classified as leiomyomas and leiomyosarcomas. GISTs are the most common mesenchymal tumours of the gastrointestinal tract and are of clinical relevance because in at least 10% to 30% of cases they are malignant. In the past, GISTs chemo and radio-resistance made treatment a challenging issue for physicians, while criteria for evaluation of the malignant potential of GISTs were lacking. Currently, identification of reliable prognostic factors and the development of molecular-targeted anticancer strategies for GIST have given new hope to these patients. The objective of the present work was to report a case of endoscopic resection of a cardia GIST.

Key words. GIST, gastric tumour, resection.

Resección endoscópica de un GIST de cardias después de una ecoendoscopia

Resumen

Antes se pensaba que los tumores del estroma gastrointestinal (GISTs) representaban tumores del músculo liso del tracto gastrointestinal y fueron clasificados como leiomiomas y leiomyosarcomas. Los GISTs son los tumores mesenquimales más frecuentes del tracto gastrointestinal y tienen relevancia clínica ya que son malignos en, por lo menos, un 10% a un 30% de los casos. En

el pasado la resistencia de los GISTs a la quimioterapia y la radioterapia hicieron de su tratamiento un tema difícil para los médicos, mientras que faltaban los criterios para la evaluación de su potencial maligno. En la actualidad la identificación de factores pronósticos fiables y el desarrollo de estrategias moleculares específicas contra el cáncer han dado una nueva esperanza a estos pacientes. El objetivo de este trabajo fue presentar un caso de resección endoscópica de un GIST de cardias.

Palabras claves. GIST, tumor gástrico, resección.

Gastrointestinal stromal tumours (GISTs) previously were thought to represent smooth muscle tumours of the GI tract and were formerly classified as leiomyomas and leiomyosarcomas. GISTs are the most common mesenchymal tumours of the gastrointestinal tract and are of clinical relevance because in at least 10% to 30% of cases they are malignant. In the past, GISTs chemo and radio-resistance made treatment a challenging issue for physicians, while criteria for evaluation of the malignant potential of GISTs were lacking. Currently, identification of reliable prognostic factors and the development of molecular-targeted anticancer strategies for GISTs have given new hope to these patients.

Within the past decade, there have been several major scientific advances in understanding the possible origin and pathogenesis of these tumours. This in turn has greatly impacted the approach to diagnosis and treatment. GISTs are defined as mesenchymal tumours arising from the gastrointestinal wall, mesentery, omentum, or retroperitoneum that express the c-kit proto-oncogene protein, a cell membrane receptor with tyrosine kinase activity.¹⁻⁸ This expression of c-kit distinguishes GISTs from true leiomyomas, leiomyosarcomas and other mesenchymal tumours of the gastrointestinal tract. GISTs represent the large majority of mesenchymal tumours of the gastrointestinal tract and therefore, the earlier

Correspondence: David Corrêa Alves de Lima
Rua Piauí, 69 – Conj. 109/110. Belo Horizonte, MG 30150-320
Brazil.
Tel: (55-31)-3241-6668
E-mail: david@biogastro.com.br

publications depicting gastrointestinal smooth muscle tumours are largely a reflection of GISTs instead of true leiomyomas or leiomyosarcomas. The objective of the present work was to report a case of endoscopic resection of a cardia GIST.

Case report

A 56-year-old woman with a previous endoscopy that revealed a gastric polyp was sent to our department to undergo a polipectomy. The upper gastrointestinal endoscopy demonstrated a neoplasia in the cardia covered by a smooth and brilliant mucosa. The tough using biopsy forceps was compatible with a subepithelial lesion (Figure 1).

The endoscopic ultrasound with 15 MHz miniprobe showed a homogeneous, hypoechoic lesion of regular forms located in deep mucosa and submucosa, with a diameter of 4 cm, compatible with a myogenic lesion (leiomyoma or GIST) (Figure 2). There were

neither cystics nor echogenic foci inside the lesion.

Physical examination, laboratory and tumour serum markers were normal. No findings were present in the imaginological investigation with a CT scan of abdomen and thorax.

An elective intra-hospitalar resection was proposed, which was done en bloc using a snare mix electrical current. In spite of waiting few minutes with the lesion snared in order to acquire violable coloration, arterial blood loss was observed after resection (Figure 3). This feature was treated using hemoclips (Figure 4). The histology assessment was suggestive of a GIST with a reduced mithotic index and free margins (Figure 5). The positive immunohistochemistry for CD 117, PS-100, desmine and vimentine confirmed the diagnosis. The patient is annually controlled with an upper gastrointestinal endoscopy and is free of lesion after a five-year follow-up.

Figure 1. The upper gastrointestinal endoscopy demonstrates a neoplasia in the cardia covered by a smooth and brilliant mucosa.

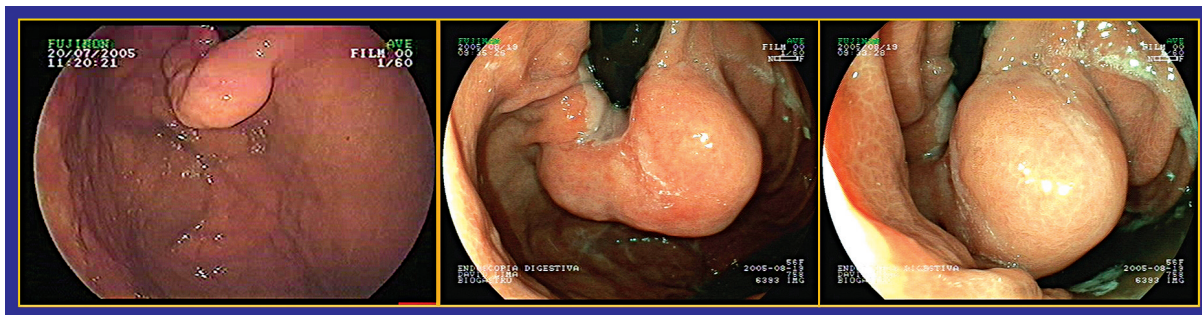


Figure 2. The endoscopic ultrasound with 15 MHz miniprobe shows a homogeneous, hypoechoic lesion of regular forms located in deep mucosa and submucosa, with a diameter of 4 cm.

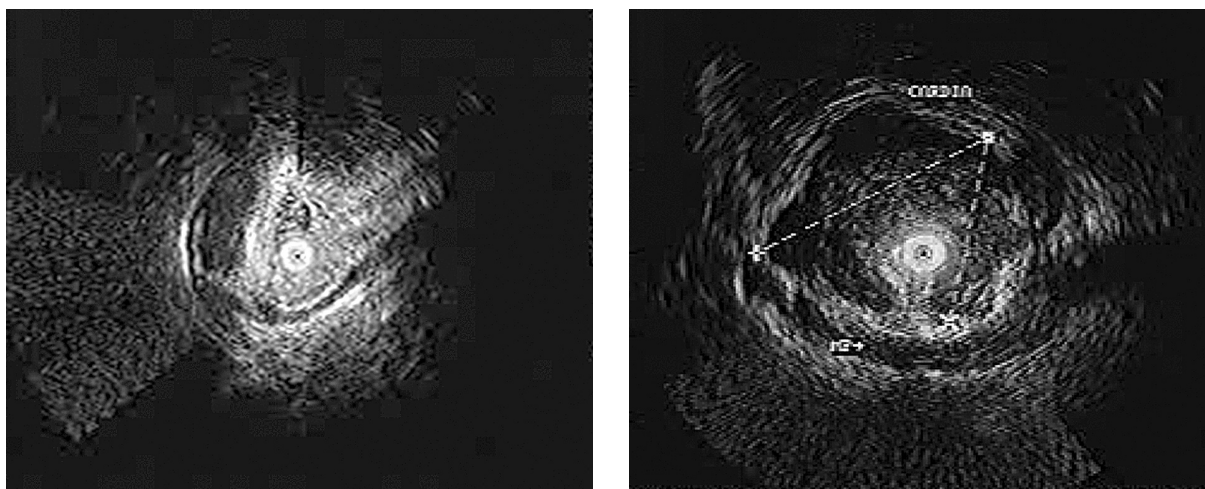


Figure 3. *En bloc* resection using a snare mix electrical current. Observe the arterial blood loss after resection.

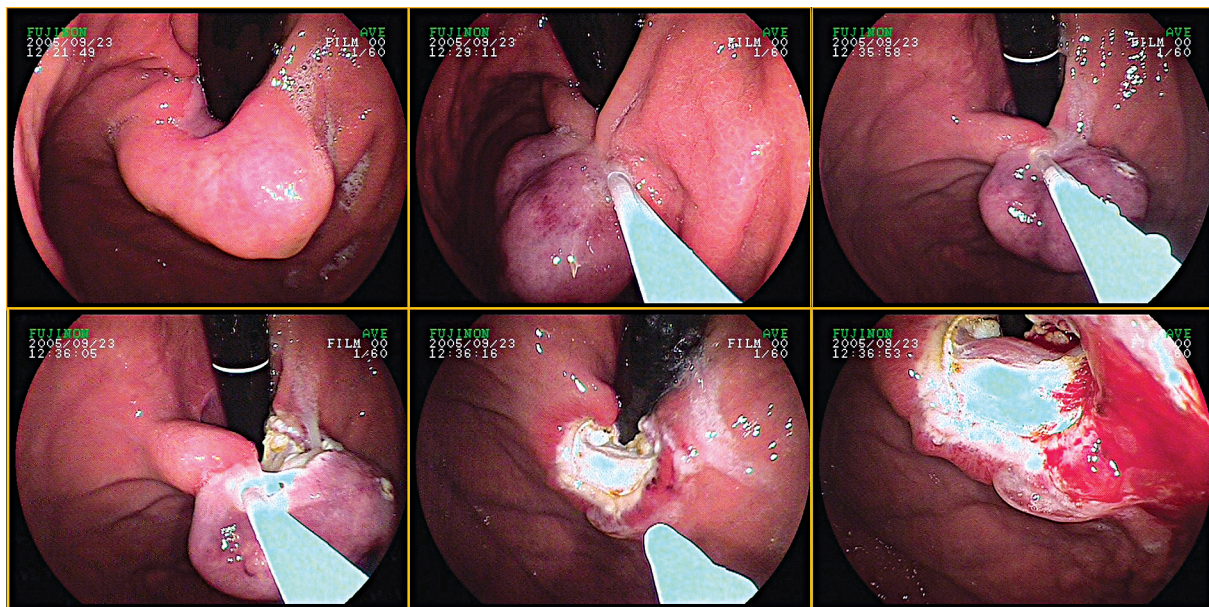


Figure 4. Arterial blood loss treated with hemoclips.

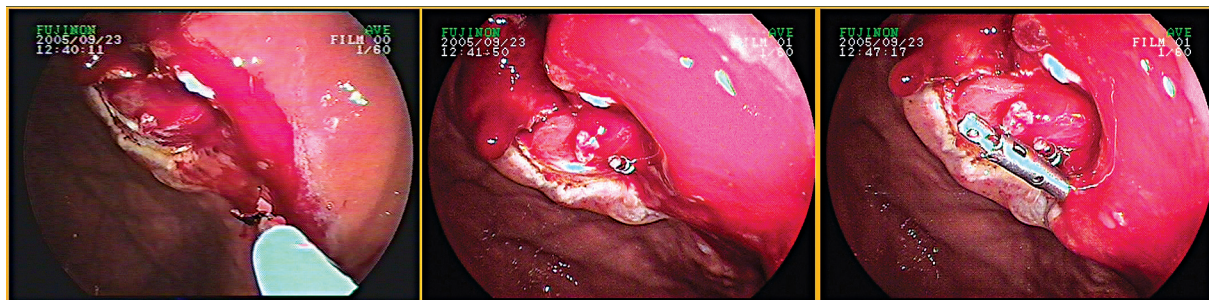
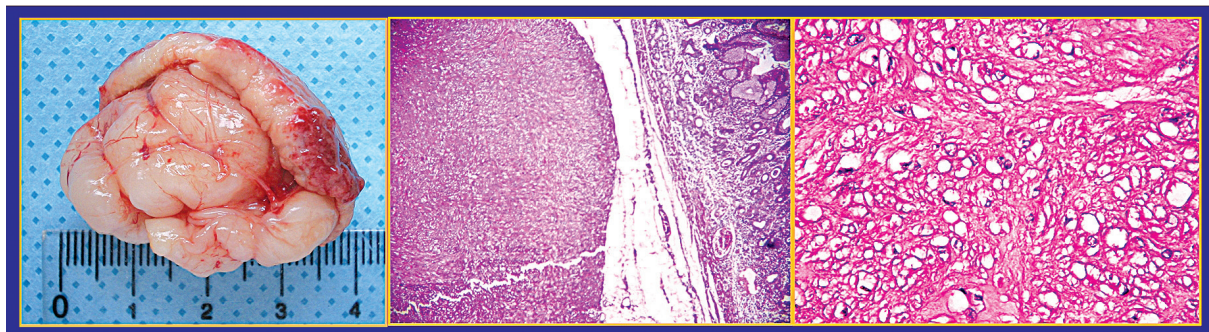


Figure 5. The histology assessment was suggestive of a GIST with a reduced mitotic index and free margins.



Discussion

The presence of a subepitelial lesion in the cardia is always a reason of concern for the endoscopist

and the surgeon. Although the GIST is the most frequent myogenic lesion in this topography and the treatment for lesions with a diameter larger than 2

cm has been preferentially surgical, it is important to stress that the possibility of a leiomyoma still existed. We must consider that any operative procedure in the cardia normally demands an esophagus-gastric anastomosis, with its potential complications. In the present case, the endoscopic ultrasound suggested the location of the lesion in deeper mucosa and submucosa with probable origin in the muscular layer of the mucosa. Considering this fact, endoscopic resection was possible.

References

1. Steigen SE, Eide TJ. Gastrointestinal stromal tumours (GISTs): a review. *APMIS* 2009;117:73-86.
2. Everett M, Gutman H. Surgical management of gastrointestinal stromal tumours: analysis of outcome with respect to surgical margins and technique. *J Surg Oncol* 2008;98:588-593.
3. Nishida T, Hirota S, Yanagisawa A, Sugino Y, Minami M, Yamamura Y, Otani Y, Shimada Y, Takahashi F, Kubota T, GIST Guideline Subcommittee. Clinical practice guidelines for gastrointestinal stromal tumour (GIST) in Japan: English version. *Int J Clin Oncol* 2008;13:416-430.
4. Bucher P, Morel P. Gastrointestinal stromal tumours (GIST). *Rev Med Suisse* 2008;4:1567-1570.
5. Scarpa M, Bertin M, Ruffolo C, Polese L, D'Amico DF, Angriman I. A systematic review on the clinical diagnosis of gastrointestinal stromal tumours. *J Surg Oncol* 2008;98:384-392.
6. Kitamura Y. Gastrointestinal stromal tumours: past, present, and future. *J Gastroenterol* 2008;43:499-508.
7. Wente MN, Büchler MW, Weitz J. Gastrointestinal stromal tumours (GIST). Surgical therapy. *Chirurg* 2008;79:638-643.
8. Hueman MT, Schulick RD. Management of gastrointestinal stromal tumours. *Surg Clin North Am* 2008;88:599-614.